




Next-Generation Aesthetics: Fingerheld Ultrasound for Simultaneous Injection and Real-Time Imaging

Benjamin Ascher¹ · Jovian Wan² · Jair Mauricio Cerón Bohórquez³ · Kyu-Ho Yi^{4,5} 



Received: 20 March 2025 / Accepted: 14 May 2025

© Springer Science+Business Media, LLC, part of Springer Nature and International Society of Aesthetic Plastic Surgery 2025

Abstract Ultrasound technology has become an essential tool in aesthetic medicine, enhancing safety and precision during injectable treatments by providing real-time visualisation of facial anatomy. However, traditional systems are hindered by size, complexity, and the inability to facilitate simultaneous imaging and injection, limiting their integration into clinical workflows. The fingerheld ultrasound demonstrated enhanced precision and safety during facial injectable procedures by enabling real-time imaging alongside injections. Its ergonomic design improved accessibility to delicate facial areas, while its portability facilitated broader clinical use. Challenges such as limited depth penetration and the learning curve for new users were noted but deemed manageable with future refinements and training programs. The fingerheld ultrasound represents a transformative advancement in aesthetic

medicine, offering simultaneous injection and imaging capabilities. With continued development, it has the potential to revolutionise facial aesthetic procedures, improving outcomes and patient safety.

Level of Evidence V This journal requires that authors assign a level of evidence to each article. For a full description of these Evidence-Based Medicine ratings, please refer to the Table of Contents or the online Instructions to Authors www.springer.com/00266.

Keywords Ultrasound · Aesthetic medicine · Dermal fillers · Real-time imaging

Dear Editor,

Ultrasonography has become an indispensable tool in aesthetic medicine, allowing real-time visualization of facial structures to enhance precision and safety in injectable treatments such as dermal fillers and botulinum toxin. By enabling the identification of blood vessels, nerves, and musculature, ultrasound reduces vascular complications and improves clinical outcomes [1–4]. However, traditional ultrasound systems have limitations that hinder their use in aesthetic procedures. Their large size, complex operation, and steep learning curve make real-time application challenging. Additionally, practitioners must alternate between injecting and monitoring the screen, affecting precision and procedural efficiency [3].

Recent advancements in portable ultrasound devices have improved accessibility but still face key limitations in depth penetration and ergonomics. Many systems struggle to visualize deep structures, limiting their effectiveness for procedures involving subcutaneous tissue, nasolabial folds, and deeper dermal layers. Additionally, ergonomic

✉ Kyu-Ho Yi
kyuho90@daum.net

Benjamin Ascher
doctorbenjaminascher@gmail.com

Jovian Wan
contact.drjovian@gmail.com

Jair Mauricio Cerón Bohórquez
jmceron14@hotmail.com

¹ SibUS-In, Paris, France

² Medical Research Inc, Wonju, Korea

³ Medical Contour, Hamburg, Germany

⁴ Division in Anatomy and Developmental Biology, Department of Oral Biology, Human Identification Research Institute, BK21 FOUR Project, Yonsei University College of Dentistry, 50-1 Yonsei-ro, Seodaemun-gu, Seoul 03722, Korea

⁵ You and I Clinic, Seoul, Korea

constraints can make traditional ultrasound cumbersome to use in delicate areas such as the nose and periorbital region, where high precision is essential [3]. This article introduces a fingerheld ultrasound probe (SIBUS-In (Safe Injection by Ultrasound), Paris, France), designed to enhance precision, ergonomics, and procedural efficiency. Unlike traditional models, this device allows for simultaneous injection and real-time imaging, addressing major limitations of conventional ultrasound systems.

The fingerheld ultrasound probe represents a major advancement in aesthetic medicine, combining portability, precision, and real-time imaging. Unlike traditional bulky probes, this compact, lightweight device offers improved maneuverability, particularly in hard-to-access regions such as the periorbital area and nasal dorsum (Fig. 1). A key advantage of this fingerheld ultrasound is its ability to facilitate real-time injection and visualization (Supplementary Video 1). Traditional ultrasound-guided procedures require practitioners to switch between injecting and monitoring the screen, which can delay treatments and reduce accuracy. By enabling continuous visualization of vascular structures, nerves, and filler placement, this technology enhances safety, minimizes complications, and improves treatment precision.

This device is highly portable, making it ideal for use in various clinical settings, including private practices, hospitals, and mobile aesthetic units. Unlike conventional ultrasound systems that require extensive setup, the fingerheld probe ensures seamless integration into aesthetic workflows with minimal disruption.

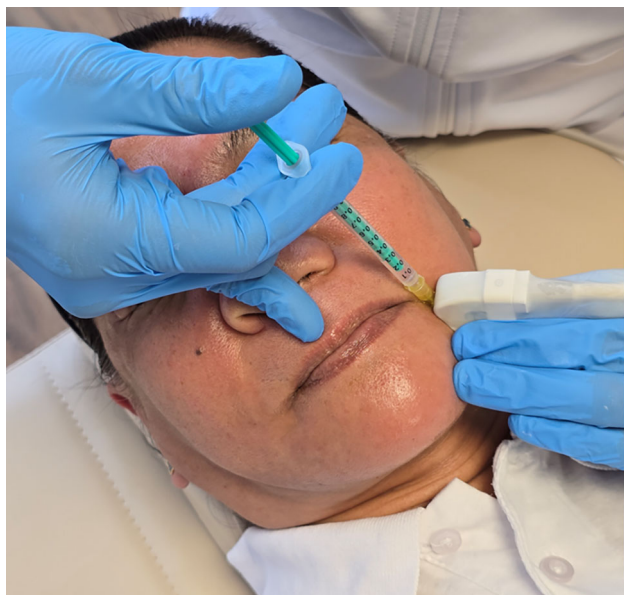

Fig. 1 Positioning of the ultrasound probe (SIBUS-In, Paris, France) during filler injection on the face

While the fingerheld ultrasound device offers significant improvements over traditional ultrasound, several limitations remain (Supplemental Table 1). The device performs well for superficial structures such as veins, arteries, and nerves but has limited depth penetration, making it less effective for deeper facial structures. This limitation is particularly notable for procedures involving deep filler placement in areas like the midface, nasolabial folds, or subcutaneous layers [5]. Future advancements could include higher-frequency probes or adaptive imaging technologies to enhance deep-tissue visualization.

Although the fingerheld design improves maneuverability, prolonged use may cause muscle strain, potentially affecting precision and speed. Future models could incorporate ergonomic handles or support mechanisms to enhance comfort during extended procedures.

Ultrasound imaging requires expertise, and interpreting facial structures during real-time procedures presents a learning curve. Structured training programs will be critical to ensure practitioners effectively integrate ultrasound-guided techniques into their practice. Future devices could feature AI-assisted imaging to aid anatomical identification and improve diagnostic accuracy [5].

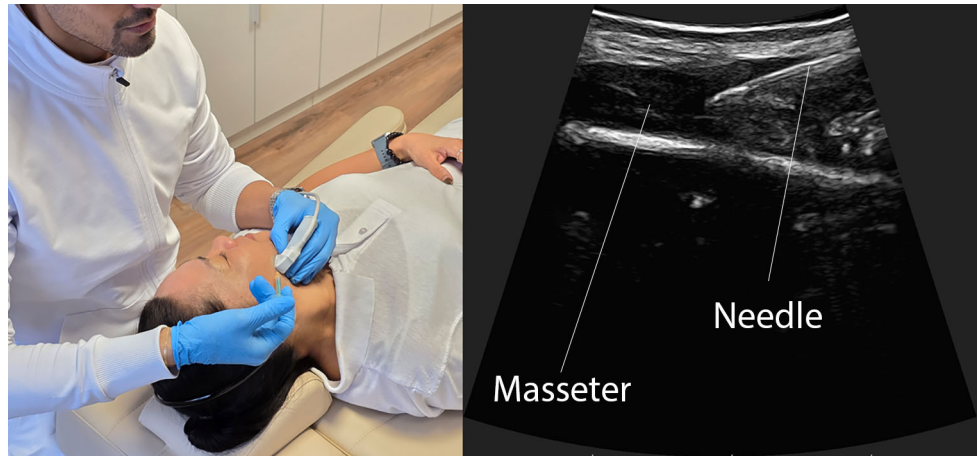While more affordable than traditional systems, the initial cost and maintenance expenses, including ultrasound gel and disposable probes, may be prohibitive for some practitioners. Scaling production and providing financial incentives for training could enhance wider adoption of ultrasound-guided procedures.

While the fingerheld ultrasound allows for simultaneous imaging and injection, screen size, refresh rate, and resolution may limit visualization of fast-moving structures such as arteries. Future iterations could feature higher-resolution displays and improved frame rates for more precise dynamic imaging.

The fingerheld ultrasound probe is a game-changer in aesthetic medicine, offering real-time imaging, enhanced precision, and simultaneous injection capabilities. Its ergonomic design and portability make it a valuable tool for improving the safety and efficacy of injectable procedures. For example, procerus injection with botulinum toxin can be performed under the guidance of SIBUS (Fig. 2). However, depth penetration limitations, ergonomic fatigue, and the learning curve remain areas for future development.

With ongoing refinements, this technology has the potential to revolutionize noninvasive facial aesthetics, elevating the standard of care while improving patient safety and clinical outcomes. Future research and technological advancements will ensure its wider adoption and continued innovation in aesthetic medicine.

Fig. 2 Ultrasound-guided botulinum toxin injection into the masseter muscle using the SIBUS system



Author Contributions Benjamin Ascher, Jovian Wan, Kim, and Kyu-Ho Yi contributed to conceptualization. Benjamin Ascher, Jovian Wan, and Kyu-Ho Yi were involved in writing—original draft preparation. Benjamin Ascher and Jovian Wan contributed to writing—review and editing. Benjamin Ascher, Jovian Wan, Kyu-Ho Yi, Jair Mauricio, and Cerón Bohórquez were involved in visualization. Kyu-Ho Yi contributed to supervision. All authors have reviewed and approved the article for submission.

Supplementary Information The online version contains supplementary material available at <https://doi.org/10.1007/s00266-025-05029-x>.

Funding The authors received no financial support for the research, authorship, and publication of this article. The products utilized in this study were donated by the injectors for the purposes of this study.

Declarations

Conflict of interest Benjamin Ascher, Jair Mauricio Ceron Bohorquez, and Kyu-Ho Yi are board members of SIBUS-In, Paris, France.

Ethical Approval The consent have been obtained from the patients.

Informed Consent For this type of study, informed consent is not required.

References

1. Schelke L, Farber N, Swift A. Ultrasound as an educational tool in facial aesthetic injections. *Plast Reconstr Surg Glob Open*. 2022;10: e4639.
2. Velthuis PJ, Jansen O, Schelke LW, Moon HJ, Kadouch J, Ascher B, Cotofana S. A guide to Doppler ultrasound analysis of the face in cosmetic medicine. Part 1: standard positions. *Aesthet Surg J*. 2021;41(11):1621–32.
3. Yi KH. Where and when to use ultrasonography in botulinum neurotoxin, fillers, and threading procedures? *J Cosmet Dermatol*. 2023;23:773.
4. Haykal D, Cartier H, Benzaquen M, et al. The growing importance of ultrasonography in cosmetic dermatology: an update after the 23rd IMCAS annual world congress (2022). *J Cosmet Dermatol*. 2023;22:222–5.
5. Hsieh A, Baker MB, Phalen JM, et al. Handheld point-of-care ultrasound: safety considerations for creating guidelines. *J Intens Care Med*. 2022;37:1146–51.

Publisher's Note Springer Nature remains neutral with regard to jurisdictional claims in published maps and institutional affiliations.